



PATIENT

Lexi Grabowski

SPECIES

Canine

BREED

Dachshund

SEX

Female Spayed

PRESENTING CLINICAL SIGNS

History: Patient presented for abdominal distension. Abdominal effusion found.

-Abnormal PE/Chem/CBC/UA Results: TP=3.8 (5-7.4) Albumin=2.1 (2.7-4.4) BUN/CREAT=28 (4-27) Calcium=7.9 (8.9-11.4) Platelet=941 (170-400) Monocytes=1260 (0-840)

ECHOCARDIOGRAM FINDINGS

2D, m-mode, color flow and doppler imaging is available. Normal mitral valve leaflets with no prolapse into the left atrial lumen. No obvious mitral regurgitation with a normal left atrial dimension. Normal LV diameter with adequate myocardial function. The tricuspid valve appears normal with no tricuspid regurgitation. Normal right atrial and ventricular diameter and morphology indicating no overt evidence of pulmonary arterial hypertension. The pulmonic and aortic valves are normal in morphology and mobility. Normal pulmonic and aortic outflow velocities with laminar flow. No obvious aortic or pulmonic insufficiency. No pericardial effusion. Large volume pleural effusion noted. No obvious cardiac masses.

CARDIAC CHART

AGE

11 years

WEIGHT

9.9lbs

INTERPRETED BY

Maggie Machen Lamy,
DVM, DACVIM
(Cardiology)

IMAGING PERFORMED BY

Tom McNeill

HOSPITAL NAME

SVS Imaging CT

REFERRING VET

Dr. Grewal

INVOICE

26636

DATE

9/29/22

CANINE CARDIAC PARAMETERS	MR VMAX (m/s)	TR VMAX (m/s)	LA/AO (Boon method)	LA/AO (Heart Base; Swe)	FS (%)	EF (%)	EPSS (cm)
NORMAL PARAMETER	4.5-5.5	<2.7	1.3	<1.6	28-40	40-100	<0.6
PATIENT	NA	NA	NM	1.2	48	82	0.1
CANINE CARDIAC PARAMETERS	HR (BPM)	AV VMAX (m/s)	PV MAX (m/s)	BODY WEIGHT (kg)	LA 2D short axis Base view (cm)	LVIDd Avg; 2D and m-mode short axis (cm)	LVIDs Avg; 2D and m-mode short axis (cm)
NORMAL PARAMETER	50-100	0.7-1.7	0.7-1.6	BELOW	BELOW	BELOW	BELOW
PATIENT	156	0.8	0.9	4.5	1.3	2.2	1.1
*Normal chamber parameters expressed as a mean value (SD)				3	1.27 (5.3)	2.46 (2.46)	1.36 (5.5)
BODY WEIGHT DEPENDENT PARAMETERS				5	1.40 (4.5)	2.74 (5.2)	1.60 (4.7)
<i>*Note: All measurements based upon multi-modal images and methods. An average value is reported.</i>				10	1.50 (3.8)	3.27 (3.5)	2.06 (3.1)
				15	1.83 (2.0)	3.71 (2.4)	2.43 (2.1)
				20	2.02 (1.9)	4.14 (2.2)	2.80 (2.0)
				25	2.18 (2.4)	4.48 (2.9)	3.10 (2.5)
				30	2.33 (3.3)	4.83 (3.9)	3.39 (3.4)
				35	2.48 (4.3)	5.17 (5.0)	3.69 (4.5)
				40	2.62 (5.2)	5.48 (6.1)	3.96 (5.4)
				50	2.88 (7.1)	6.07 (8.3)	4.46 (7.4)

Adapted from June Boon, Veterinary Echocardiography, 1998
Rishniw M and Hollis NE, J Vet Intern Med 2000; 14:429-435
Hansson et al, Vet Rad and Ultrasound 2002
Bonagura et al. Echocardiography: principles of interpretation, Vet Clin North Am 15:1177, 1995

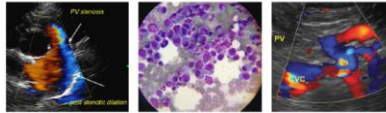
INTERPRETATION OF THE FINDINGS & FURTHER RECOMMENDATIONS

Overtly normal cardiac dimensions and function, with no obvious dysfunction or dilation of the left heart. No significant valvular leaks are visualized, and no evidence of pulmonary hypertension.

No cardiac cause for bicavitary effusion is identified in this study. Consider further evaluation, such as fluid sampling/cytology, thoracic CT scan, etc. Consultation with an IM specialist is recommended.

IMAGING PERFORMED BY

svsmobileimaging.com 309-737-3070



PATIENT

Lexi Grabowski

Monitor for development of a heart murmur, cough, labored breathing, exercise intolerance or collapse episodes.

SPECIES

Canine

A recheck echocardiogram is recommended should a significant murmur develop, or signs of cardiac compromise be noted in the future.

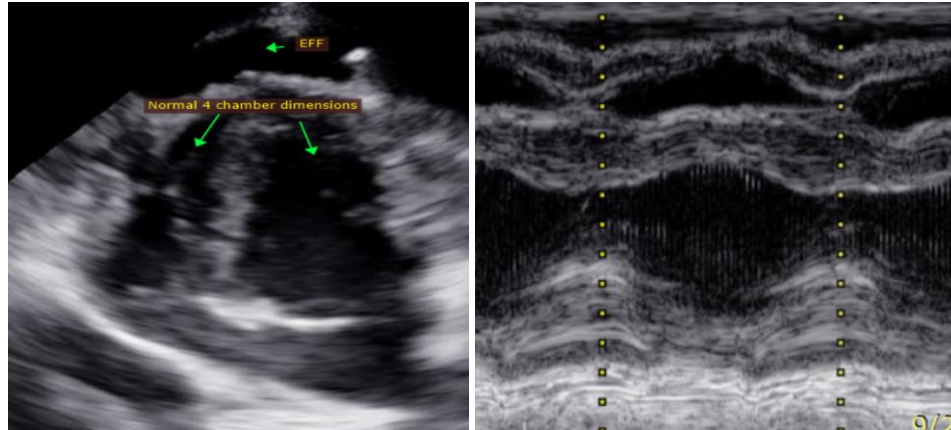
BREED

Dachshund

IMAGES

SEX

Female Spayed



AGE

11 years

WEIGHT

9.9lbs

The information and recommendations provided are based on the images presented by the referring veterinarian. No evaluation can be communicated regarding pathology that was not visible in the image/video clips provided.

INTERPRETED BY

Maggie Machen Lamy,
DVM, DACVIM
(Cardiology)

Thank you for this referral. If the clinical or image interpretation does not parallel your findings or if I can be of any further assistance, please contact me.

Maggie Machen Lamy, DVM
Diplomate of the American College of Veterinary Internal Medicine (Cardiology)
info@sonopath.com

IMAGING PERFORMED BY

Tom McNeill

HOSPITAL NAME

SVS Imaging CT

REFERRING VET

Dr. Grewal

INVOICE

26636

DATE

9/29/22